Ivane Javakhishvili Tbilisi State University

Translational and Clinical Medicine - Georgian Medical Journal

Vol 4, No 1

March

Publishers:

Ivane Javakhishvili Tbilisi State University (TSU);

Georgian Medical Association (GMA)

Tbilisi, Georgia

www.tcm.tsu.ge

ISSN: 2346-8491 (online)

2019

Table of Contents

Research Articles

1. Leila Patarashvili, Keti Tsomaia, Manana Kakabadze, Dimitri Kordzaia, Ilia Chanukvadze.
   Perivascular connective tissue sheath and portal tracts in mammals----------4-7

Literature Review

2. Nino Karumidze, Diana Dzidziguri.
   The role of somatic polyploidy in various liver pathologies in rats----------8-10

3. Nugesha Grigalashvili.
   Management of Infertility in Women with Ovarian Endometrioma----------11-14

4. Ioseb Begashvil.
   Minimal fresh gas flow anesthesia----------15-22

Perivascular connective tissue sheath and portal tracts in mammals

Patarashvili L.[1] Tsomaia K.[1,2] Kakabadze M.[2] Kordzaia D.[1,2] Chanukvadze I.[3]

Abstract

Introduction: Many hepatic pathologies associated with the ductular reaction, changes of biliary mucosal glands, inflammation with leukocyte infiltration, etc. involve the liver portal tracts. The number of investigations indicates the role of portal tracts in the liver regeneration, innervation of the hepatic parenchyma; also, the portal tracts are important for surgeries aiming to treat the biliary atresia or conduct the liver graft transplantation.
To clarify the role of the portal tracts in development of various hepatic disorders, as well as successful implementation new interventions using the elements of a portal complex, requires translational investigations in different animals and therefore the studies of their portal tracts architecture for this purpose.
Method: We studied the architecture of the portal tracts of humans, canines and rats with the following comparative analysis. The methods of macerating preparations, corrosion casts of tubular structures, histology (histotopography, histochemistry, immunohistochemistry) were used.
Conclusion: It was revealed that the overall architecture of the human, dog and rat portal tracts and the location of the elements in them is alike: the portal veins are surrounded by arteries and bile ducts, which are localized more peripherally – bordering liver parenchyma. However, in the animals the arterial-fibrous and biliary fibrous layers, which are the typical structures in humans, are less clearly developed. Humans' and dogs' bile ducts are supplied with mucous glands, while in rats, these structures are replaced by a periportal biliary plexus. This fact should be related to the absence of gallbladder and therefore, to the different conditions of bile drainage. **(TCM-GMJ March 2019; 4(1):P4-P7)**

Keywords: Connective tissue sheet; Portal tract; Mammals;

Introduction

Pathologies such as cirrhosis and bile congestion are directly reflected on morphology of liver portal tract (1). The ductular reaction (2,3), inflammation with leukocyte infiltration (4), activity of biliary mucosal glands, as well as links between biliary and lymphatic channels (5,6,7,1) are developed in the area of portal complex surrounded by perivascular fibrous sheath derived from Glisson's Capsule. The role of portal tracts in the liver regeneration (8), as well as in ensuring innervation of the hepatic parenchyma (9) causes great interest. The knowledge of the architectonics of the portal tracts is important in terms of intervention due to biliary atresia (4) or for successful transplantation of the liver grafts (10). The porto-caval connective tissue links, discovered by us (11) increased the interest towards the research of morphology of portal tracts and particularly after revealing that these portocaval connective tissue links might influence on the development of various hepato-biliary pathologies (e.g. formation of hepatic vein thrombosisin case of cholangitis)or may be used for the formation of intrahepatic portocaval shunts (5,12,1). However, the clarification the role of portal tracts in pathogenesis of the various deseases, as well as introduction of new interventions based on the usage of their elements needs conducting additional translational researches in various experimental models. This, in its turn, requires the study of the pecularities of portal tracts in different animals, both under normal as well as pathilogical conditions.
We aimed to conduct the comparative analysis of morphology of the portal tracts of humans, canines and rats.

From the [1]Iv. Javakhishvili Tbilisi State University (TSU), Tbilisi, Georgia [2]Alexsandre Natishvili Institute of Morphology, TSU, Tbilisi, Georgia; [3]Tbilisi State Medical University
Received September 22, 2018; accepted November 10 , 2018.
Address requests to: Leila Patarashvili, TSU PhD Student
E-mail: leliko1990@gmail.com
Copyright © 2019 Translational and Clinical Medicine-Georgian Medical Journal. Published online www.tcm.tsu.ge

Materials and methods

The following was used for research: a) The-archive material included 58 slices of macerating preparations,containing hepatic portal tracts, as well

as 0.5cm slices from the 100**μm** of the same areas, obtained from the corpses of adults (whose death was not related with liver pathology) of both sexes.The part of the slices was prepared by the combination of various colored ink and gelatin mixture of the portal vein, biliary tract and/or hepatic artery (proportion 1:3) following the preliminary injection (I. Chanukvadze's archive, at the Chair of Operative Surgery and Topographic Anatomy of Tbilisi State Medical University);b) The archive material, includedcorrosive preparations of hepatic tubular structure of 6 adult mongrel (street) dogs of both sexes (Made of latex manufactured by NAIRIT and tissue disruption in 90% H_2SO_4); as well as up to 0,3cm thikslicesfrom 30μm, prepared from the 5 dogs' liver fragments, containing portal tracts. The part of the slices was prepared by the combination of various colored ink and gelatin mixture of the portal vein, biliary tract and/or hepatic artery (proportion 1:3) following the preliminary injection (The animals were control animals in the series of studies of the biliary engorgement [D. Kordzaia Archive, at the Chair of Operative Surgery and Topographic Anatomy of Tbilisi State Medical University]); g) The slices, from 4μm up to 100μm thick, containing the portal tracts of the livers of 16 rats of both sexes, which died during the implementation of the various operative models of the ongoing scientific research within the ongoing scientific research Aleksandre Natishvili Institute of Morphology of Ivane Javakhishvili Tbilisi State University.

The mentioned slices were studied by using binocular magnifying glass or light microscope (Micros [Austria]),by the hematoxylin-eosin, Van Gieson method (Weyhert picro-fuchsin) and after painting with Masson Trichrome (additionally, part of the slices was painted by reticulin - for revealing reticular fibers); The mucicarmine stain was applied for revealing mucosal biliary glands.Part of the preparations were marked by cytokeratin (CK19, CK7, AE1/AE3), stem cells (OV6), smooth muscle actin(SMA, NCAM) markers.

As a result of histological studies (including histotopographic) of the preparations, the typical description of human liver portals has been developed, which covered all the structures located at this site, their interpositioning and interconnection.

The abovementioned was followed by studying the dog and rat portal tracts and identification of the structures within them, taking into account the description of the human liver portal tract.

We have conducted tabular comparison of the obtained datasimilarly to what was performed by W. A. Beresford and D J. M. Henninger (13), to reveal the similarities and differences between the livers of vertebrates.

Results and discussion

Results of the research are presented in the table N1. The table contains general description of portal tracts of humans, dogs and rats and at the same time it gives part of the digital photoes and schemes of these portal tracts for illustration.

Conclusion

The overall architecture of the human, dog and rat portal tracts and the location of the elements in them is alike: the portal veins are surrounded by arteries, followed by bile ducts. The nerves and lymphatic vessels are "scattered" in the portal area. In addition, the smaller the dimensions of the liver and therefore its tubular structures are, the thinner the fibrous sheath of the portal veins, hepatic arteries and bile ducts is.Also, the arterial-fibrous and biliary fibrous layers are less clearly developed and do not organize the circular sheath.Human and dog bile ducts are supplied with mucous glands, while in rats, these structures are replaced by a periportal biliary plexus. This fact, as well as presence in "larger dozes" of the smooth muscular fibers in these ducts, should be related to the absence of gallbladder and therefore, to the different conditions of bile drainage.

Acknowlegement

This work was supported by Shota Rustaveli National Science Foundation (SRNSF) [DP2016_22, New Interfaculty Interdisciplinary Structured PhD Programme "Translational Biomedicine" (Direction – "Hepatology")].

References

1. Kordzaia, D., Chanukvadze, I. & JM. Functional Anatomy of Intrahepatic Biliary System (Clinical and Experimental Data). In: Bile Duct: Functional Anatomy, Disease and Injury Classification and Surgical Management. Nova Science Publishers, Inc; 2014. p. 1–87.
2. Desmet V, Roskams T, Van Eyken P. Ductular reaction in the livers. Pathology-Research and Practice. 1995 Jul 1;191(6):513-24.
3. Roskams TA, Theise ND, Balabaud C, Bhagat G, Bhathal PS, Bioulac-Sage P, Brunt EM, Crawford JM, Crosby HA, Desmet V, Finegold MJ. Nomenclature of the finer branches of the biliary tree: canals, ductules, and ductular reactions in human livers. Hepatology. 2004 Jun;39(6):1739-45.
4. Moreira RK, Cabral R, Cowles RA, Lobritto SJ. Biliary atresia: a multidisciplinary approach to diagnosis and management. Archives of pathology & laboratory medicine. 2012 Jul;136(7):746-60.

Humans

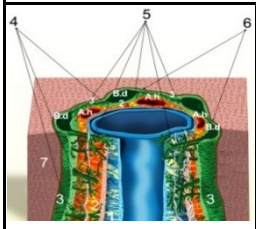

Fig 1. *Vasculo-fibrous architecture of the major portal tract (per I. Chanukvadze.)*
V.P. Portal vein; B.D. Bile ducts; A. Hepatic arteries. 1. Fibrous sheath of the portal vein; 2.Fibrous inter-arterial sheath; 3.Parabiliary connective tissue; 4.Mucous biliary glands; 5. Lymph ducts; 6. Perivascular fibrous capsule; 7. Hepatic tissue.

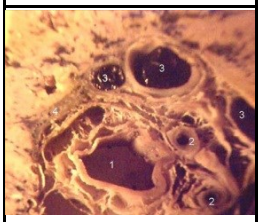

Fig 2. *Lobar portal tract; 1. portal vein; 2. artery; 3. bile ducts are filld with ink-gelatine mixture; 4. mucosal biliary gland. (Binocular Lupe; initial X 30).*

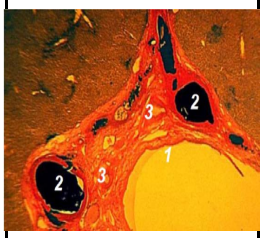

Fig 3.*Histotopogram of the portal tract. 1.Portal vein; 2.Bile ducts (filled by ink gelatin); 3. Hepatic artery. (Picrofuxin; initial X30).*

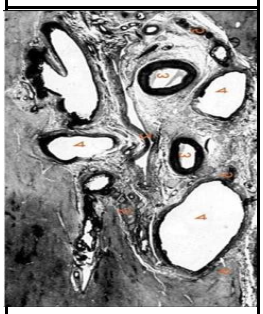

Fig 4. *Histotopogram of the portal tract. 1.Portal vein; 2.Bile ducts 3. Hepatic artery.3.Parenchyma. (H&E; initial X30).*

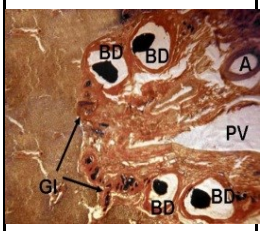

Fig 5. *Histotopogram of the portal tract. PV-Portal vein; BD - Bile ducts (filled by ink gelatin); A-Hepatic artery; Gl – Biliary glands. (Picrofuxin; initial X30).*

The portal complex of humans are represented by three consecutively arranged circular sheaths - fibrous-portal, fibrous-arterial and fibrous-biliary layers - enveloped within a fibrous sheath of the whole portal complex –a perivascular fibrous sheath, representing the intrahepatic derivate of Glisson's capsule.

The collagen, reticular and elastic fibers, as well as smooth muscle fibers are distinguished in the composition of all mentioned layers and the walls of the branches of bile duct, portal vein and hepatic artery, though in dramatically different correlationsthey represented relatively to a less extent in the vein and duct walls, while they create quite well expressed layer in the artery walls(14,15).

The fibrous-biliary layer is located most peripherally. It is represented by branched gross and small caliber ducts, intra- and extramural mucosal biliary glands and peribiliary/ periglandular connective tissue, which is immediately surrounded by firmly attached peri- vascular fibrous sheath. The periglandular connective tissue represents the lateral branches of peribiliary connective (fibrotic) tissue. Its recesses contain the extramural portions of mucosal biliary glands. The lymphatic network of portal tract is in close contact with biliary structures.The blind glandular terminals of extramural mucosal glands are related to the lateral surfaces of adjacent bile ducts. However, the anterior (internal) surface of the bile ducts facing the center of the portal tract are in close relationship with the fibrous-arterial layer. The posterior (external) surface of the bile ductsare facing the parenchyma. Both of these surfaces are free from mucosal biliary glands or the glands situated on these areas are small and don't occupy the space inside the portal tracts (intramural glands).

We have confirmed that connecting tissue fibers are located not only in the above described layers of the portal complex and in the adventitia of existing ductular structures, but they move to the parenchyma and appear in the Disse's spaces, where they form the soft matrix for the sinusoids.This data coincide with the results obtained in the study of Klin Wochen-schr (14,16,17). The hepatic efferent nerves are located in the portal tracts, which according to ***McCuskey*** *(9)*representaminergic, cholinergic,peptidergic, and nitrergic nerves.Their fibers penetrate to the liver parenchyma and participate in the regulation of the liver cells function and blood circulation in the sinusoids.

Canines

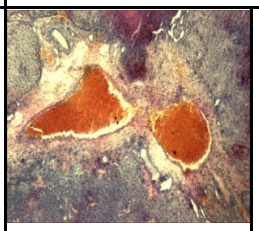

Fig 6. *Histology of portal tract (close to the level of branching of portal vein). 1. Portal vein; 2. Hepatic artery; 3. Bile duct; Arrow - Perivascular fibrous capsule. (H&E; initial X30)*

Fig 7. *Corrosion Casts of tubular structures of the portal tract. 1. Portal vein; 2. Hepatic artery; 3. Bile duct; 4. Leakage of latex due to detoriation of the bile duct. (Binocular Lupe; initial X 30).*

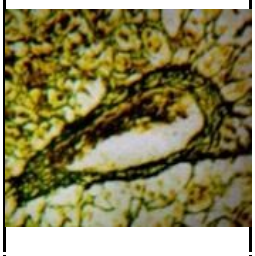

Fig 8.Reticular fibers of portal tract. The fibers surrounding the portal complex are continued into the fibers of Disse's space. (Reticulin; *initial X 400).*

Fig 9. *Corrosion cast of Bile duct. 1. Bile duct; 2. Biliary gland. (Binocular Lupa; initial X 50).*

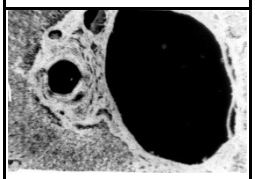

Fig 10. *Part of the histotopogram of the portal tract. 1.Portal vein; 2.Bile ducts 3. Hepatic artery. 4.Area of opening of biliary glands into bile duct; (H&E; initial X100)*

The structure of the canine portal tract is principally identical to the structure of human portal tracts. At the same time, the fibrous layer of the portal veins, hepatic arteries and bile ducts is thinner.The bile ducts and arteries in the tract maintain such topography, as noted in the human portal tracts. Although, in contrast to them, the arterial-fibrous and biliary fibrous layers are less clearly defined, as well as whole circular sheath.There are smooth muscle fibers among the connective-tissue fibers, in the walls of the portal vein and the branches of the bile duct. The similar fibers develop the well-formed sheath within the walls of the artery.

The inner space of the Capsula Perivascula, represents the area, where the portal vein,branches of the hepatic arteries (several) and bile ducts (several), biliary mucosal glands, lymph vessels and nerves are placed among the connective tissue fibers,located with the different density. As in case of humans, the biliary mucosal glands join the bile ducts along the two opposite lines – on the surfaces of the bile ducts that aredirected neither towards the portal vein, nor to the parenchyme.These two surfaces are free from mucosal biliar glands or the glands situated on these areas are small and localized intramurally.

The connective tissue fibers, originating from the portal tracts and heading along the Disse's spaces, are noted in the dog's liver, just like the human liver. The location and branching of the nerve fibers of the portal tract is the same as in the human liver.

Rats

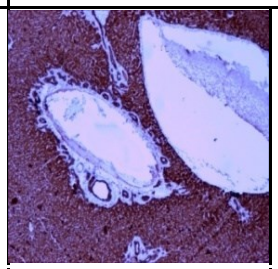

Fig 11. *Portal tract and Hepatic Vein. 1. Portal vein; 2. Hepatic vein; 3. Bile duct; 4. Periportal biliary plexus; 5. Parenchyma. (AE1/AE2); initial X 100).*

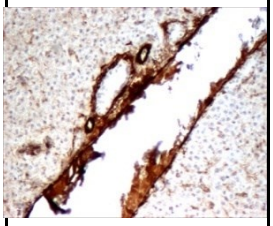

Fig 12. *Fragment of portal tract. 1. Portal vein; 2. Bile duct; 3. Smooth muscle fibers in the Fibrous sheath of the portal vein and wall of bile duct; 4. Parenchyma. (SMA; initial X100).*

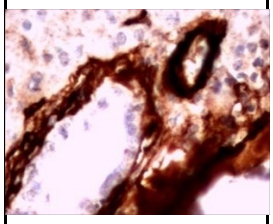

Fig 13. *Fragment of portal tract. 1. Bile duct;; 2. Hepatic Artery; 3. Smooth muscle fibers in the walls of Hepatic Artery and Bile duct; 4. Parenchima. (SMA; initial X100).*

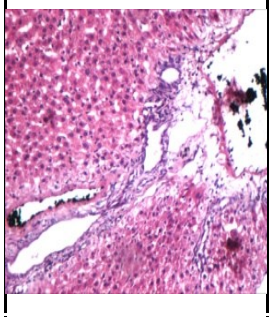

Fig 14.*Histology of the part of the portal tract. 1.Portal vein; 2.Bile ducts 3. Hepatic artery. 4.Parenchima (H&E; initial X100)*

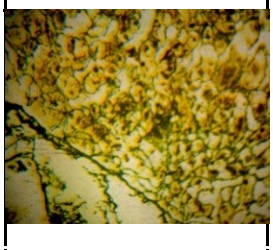

Fig 15.*Reticular fibers of portal tract. The fibers surrounding the portal complex are continued into the fibers of Disse's space. (Reticulin; initial X 200).*

The structure of the rat portal tracts repeat the structure of human and dog portal tracts in principle. At the same time, the fibrous sheath of the portal veins and bile ducts is even more thinner than in dogs.Arteries and bile ducts in the tract maintain the same topography towards the portal vein as in the human and dog portal tracts, athough the arterial-fibrous and biliary fibrous layers are not identified unlike them, as the whole circular sheath.

The inner space of the Capsula Perivascula, represents the area, where the portal vein,branches of the hepatic arteries (several) and bile ducts (several), lymph vessels and nerves are placed among the connective tissue fibers, located with the different density. Smooth muscular fibersdetected in the thickness of the wall of the bile ducts in larger quantities(In some areas they create sheath-like structure).

Unlike humans and dogs, rats do not have mucosal biliary glands:they are "replaced" by periportal biliary plexus, which on the one hand is linked to bile ducts, and on the other hand with intralobular (Hering) ductules and bile capillaries. Connective tissue fibers located in the rat liver parenchyma (Disser's spaces) are much more soft and lesser in quantity than it is observed in human or even in the dog's liver.

The location of the nerve fibers in the portal tract more or less repeats their topography in human and dog portal tracts.However, as confirmed, in contrast to them, do not provide fibers inside the liver lobules (9)

5. Chanukvadze I. M. Structure and Connections of Fibrous Sheaths of Portal Complex and Hepatic Veins. Collections of Scientific Works of Tbilisi State Medical Institute., 1989, #1:11
6. Chanukvadze I, Archvadze V. Surgical anatomy of main intrahepatic portal tracts. Zentralblatt fur Chirurgie. 2003 Nov;128(11):958-62.
7. I.Chanukvadze, V.Archvadze, M.Soreli, G.Gudjabidze. Bilio-vascular architecture of main magistral portal tracts. Critical Care & Catastrophe Medicine. 2012; 1: 77-81
8. Dezső K, Rókusz A, Bugyik E, Szücs A, Szuák A, Dorogi B, Kiss M, Nemeskéri Á, Nagy P, Paku S. Human liver regeneration in advanced cirrhosis is organized by the portal tree. Journal of hepatology. 2017 Apr 1;66(4):778-86.
9. McCuskey RS. Anatomy of efferent hepatic nerves. The Anatomical Record Part A: Discoveries in Molecular, Cellular, and Evolutionary Biology. 2004 Sep 1; 280(1):821-6.
10. Chaib E, Ribeiro Jr MA, Saad WA, Gama-Rodrigues J. The main hepatic anatomic variations for the purpose of split-liver transplantation. InTransplantation proceedings 2005 Mar 1 (Vol. 37, No. 2, pp. 1063-1066). Elsevier.
11. Chanukvadze I.M. Construction and interactions of paravasal connective tissue structures in the liver. PhD thesis. Tbilisi State Medical Institute, 1979.
12. Sareli M, Chanukvadze I, Valeanu A, Zippel DB, Shapiro R, Papa MZ. The posterior intrahepatic approach to the left portal pedicle using the ligamentum venosum: anatomical basis. Surgical and radiologic anatomy. 2009 Dec 1;31(10):809.
13. Beresford WA, Henninger JM. A tabular comparative histology of the liver. Archivum histologicum japonicum. 1986;49(3):267-81
14. Shogo Hayashi, Gen Murakami, Aiji Ohtsuka, Masahiro Itoh, Takashi Nakano And Yoshitaka Fukuzawa; Connective tissue confi guration in the human liver hilar region with special reference to the liver capsule and vascular sheath. J Hepatobiliary Pancreat Surg (2008) 15:640–647;
15. Lefkowitch JH. Special stains in diagnostic liver pathology. In Seminars in diagnostic pathology 2006 Aug 1 (Vol. 23, No. 3-4, pp. 190-198). WB Saunders).
16. Rauterberg J, Voss B, Pott G, Gerlach U. Connective tissue components of the normal and fibrotic liver. Klinische Wochenschrift. 1981 Jul 1;59(14):767-79.
17. Pott G, Rauterberg J, Voss B, Gerlach U. Connective tissue components of the normal and fibrotic human liver. Klinische Wochenschrift. 1982 Jan 1;60 (1):1-7.

The role of somatic polyploidy in various liver pathologies in rats

Karumidze N. Dzidziguri D.

Abstract

Introduction: Polyploidy is a widespread phenomenon in nature multiple increased content of the chromosomes 4n, 8n, 16n, etc). The frequency of its occurrence varies in different classes of organisms. The highest ploidy characterizes protozoans. Polyploid is relatively rare in multicellular organisms, among which such hermaphrodites are distinguished with the content of high-ploidic cells as for example mollusks (128n). The plant and animal bodies stand in marked contrast in terms of poliploydy as well. High vitality and fertility of polyploidic plants provided the basis for the process of applying high ploidic plants as the raw material in the selection. In case of mammals, polyploidy is most intensively studied in on the example of the liver, as it belongs to that small number of organs, for which normally characteristic polyploidy is described in all species. At the same time, polyploidization is a process initiated in the destructive tissue of liver in the conditions of various pathologies. Despite this, biological importance of polyploidy and its signaling pathways are not yet fully studied

Method: We have reviewed literature in the next scientific databases: PubMed and Google Scholar. Articles were browsed by using advance search tools and filtered all open accessed articles with next keywords in title and/or abstract: *Liver Regeneration; Liver cell, Polyploidy; Liver pathologies; Liver injury; Pathways, mechanism of poliploidy;*

Conclusion: According to several hypotheses in literature, polyploidy is associated with maturation of hepatocytes and terminal differentiation protects against oxidative stress and damages caused by various pathogens and increase the functional activity of hepatocytes. Comparative study of interconnected cascade signaling pathways, averaged by protein kinases, regulating liver restoration under normal and pathological conditions by using various experimental models.

(TCM-GMJ March 2019; 4 (1):P8-P10)

Keywords: Liver; Poliploidy; Regeneration;

Introduction

Study of molecular mechanisms of reparative regeneration of organs of the mammals remains the topical problem of medicine and biology. In this respect, liver is studied especially intensely, as under normal and pathological conditions, as it is known, the mechanisms of its restoration provide maintenance of hystoarchitectonics and functional activity of the organs as well as metabolism and ultimately the homeostasis of the whole body. Therefore, it is obvious that there should exist rapid and efficient possibility of recovery of the liver lesions, caused by various factors. This is a unique regeneration ability of the liver, which implies full restoration of body mass and function. This makes liver different from other organs, which are healed up by scarring after lesion (1,2,3,4).

It is known that reparative regeneration of the liver in response to the resection, as , is reached by proliferation of hepatocytes, polyploidization and hypertrophy. Their percentage share in the process of mass and function restoration is thoroughly studied (Approximately 50%: 30%: 20%, respectively). However, there is a relatively little information aboutthe fact that liver restoration does not always occur with all three above mentioned mechanisms of regeneration and/or is taking place differently in terms of time. Thus, it is shown that the restoration of the cholestasic liver of the rat at the initial stage occurs only through polyploidization, without the increase of the quantity of cells (5); After partial hepatactomy, restoration of hepatic weight without proliferation is described in Skp2-deficient mice. In this case, it is shown the increase of the hepatocytes ploidy in the response to trauma too (6). The growth of DNA ploidy is also described in different tissues of mammals (heart, liver, cornea) (7). As for the model of the alimentary dyslipidemia, it is established that application of regeneration mechanism depends on the duration hepatogenic ration and degree of lesion. In case of steatosis (30th day) only the hypertrophy of cells is noticed, as for the steatohepatitis (90th day) the polyploidization of cells and in case of the the fibrosis (180 days) proliferation of immature cells. It follows from the above mentioned that in some pathologies the liver restoration is achieved by the quantitative increase of high-ploidic cells. However, it is not fully understood the activation/ inactivation processes of which signaling paths provides their appearance in particular cases.

Polyploidy, i.e. multifold increase of the number of chromosomes in the cell (4n or 8n) was first described in plants about 100 years ago. This is a widespread physiological condition in plants, and in particular in angiosperms (8), also in fishes and amphibians (9). It should be

From the I. Javakhishvili Tbilisi State University, Faculty of Medicine;
Received September 19, 2018; accepted November 30 , 2018.
Address requests to: Karumidze Nino
E-mail: nino.qarumidze0861@med.tsu.edu.ge
Copyright © 2019 Translational and Clinical Medicine-Georgian Medical Journal. Published online www.tcm.tsu.ge

noted that the degree of polyploidization varies for different species (10).

Polyploidy is also characteristic for mammals. The multifold increased set of chromosomes can be found in such terminally differentiated cells as: megakaryocyte, cardiomyocytes, trophoblast giant cells, Purkinje cell, retinal ganglion cells and hepatocytes (11,12,13,14,15,16). Polyploidy, or multifold increase in chromosomes in the cells are usually considered result of anincompletemitosis. In particular, after the reception of the signal, there occurred endoreduplication (form of endometriosis), or DNA duplication in the cells. After moving to the mitosis phase, karyokinesis and cytokinesis and/or just cytokinesis are blocked in these cells, which is accompanied by creation of two-nuclear and single nuclei cells. After leaving the cycle, such cell can perform specific functions throughout life. As for their breeding, Polyploid cell in interfaces, following doubling of DNA, should definitely go through all the stages of mitosis (13,17,18,19,20,21). It is noteworthy that during viral infections (mononucleosis, hepatitis, etc.), there was revealed an alternative way of producing polyploid cells, that implies merging cells (22).

Polyploidization of parenchyma cells is very important but not the only criteria in order to assess the regenerative processes to current in the liver Polyploidization of hepatocytes is widely studied. The formation of polyploid is based on three following processes: 1.Re-duplication; 2. Merging somatic cells or their nuclei; 3.Not separation of chromosomes during meiosis. Accordingly, the somatic and meiotic polyploidy is distinguished. Two basic forms of somatic polyploidization are distinguished: physiological and pathological (23). The liver's physiological polyploidization is considered as the age-dependent process that usually begins at the early stage of postnatal development and continues throughout life. Tetraploid cells derived from the incomplete mitosis of proliferative diploid hepatocytes are forming tetraploid and so on high ploidy hepatocytes following the additional mitosis cycle. For example, in case of the rodents during the first 3 weeks after birth, the liver is mainly represented by diploid cells (2n). From the 4th week, their proportionate number is reduced and two-nuclear diploid or tetraploid (2x2 n) and single-nuclei tetraploid (4n 8n) cells appear. Octoploid (two-nuclear 2x4n and single nuclei 8n) cells are intensely multiplied from 2 to 3 months from the birth (24,15,25, 26). In humans, polyploid cells appear in the postnatal period during liver development (hepatogenesis). Their number is more or less stable during maturity, but during aging the rapid increase of high polyadic liver cells is observed. For example, their number in mice is 90% and in people 40% (24).

It is believed that the increase in the number of polyploidic cells along with the aging of organism is the result of uneven growth of organ systems that are caused by suppressed mitotic activity in some organs. Polyploidization of the part of the liver tissue eliminates the imbalance in growth. If we artificially stop the growth of the organism then the polyploidization of the organs with low mitosis will be also suspended. Therefore, the process of polyploidization of hepatocytes is considered as an evolutionary adaptation mechanism (13), molecular basis of which is still unclear (27) In addition, it is shown that the higher the cells ploidy is, the lower their mitosis activity (28). It is also noteworthy that polyploidy is disastrous if it is revealed during embryonic development. Consequently, sometimes the cause of spontaneous cessation of pregnancy is the cause of death of such embryos (3).

In mammals the ploidy of the liver cells increase in case of different pathological processes (pathologic polyploidization), as a result of loss of the liver mass and liver lesion (5,29) The following are considered to be pathological process: mechanical hepatic injury (eg. hepatectomy), chemical liver injury (by a variety of toxic substances), radiation, oxidative and stress, tumor processes (30).

It is shown that in order to restore the function after bilateral adrenallectomy, the compensitive mechanism is launched in the liver tissue of white rats, that causes multyfold increase of genome in hepatocytes. In such conditions (hormonal imbalance) initiation of rapid division (early mitosis) of the mentioned cells in the resected liver and partial restoration of the function of the organ is reached. In order to restore function, the accumulation of high-ploidic cells in the liver parenchyme occurs also aftercommon bile duct ligation. It should be noted that in contrast to the adrenalectomized animal in case of cholestasis their accelerated transition in the mitosis phase does not occur.

It has been more than not one year how the number of articles, concerning the studies of the correlation of liver diseases and the autonomic nervous system, has been significantly increased. It is shown that cutting the liver branch of the vagus nerve weakens, but does not suppress the regeneration process, while subdiaphragmatic vagotomy inhibits restoration growth. According to the data available today, participation of the vagus nerve can be explained by the direct and specific impact of the so called vagus factor (e.g. hepatocytes growth factor - HGF) in liver regeneration. It is also noteworthy that the data on the role of subdiaphragmatic vagotomy in liver regeneration in some cases is mutually exclusive. Such number of articles, confirms the necessity of more thorough research of participation of this system in regulation of body growth and regeneration (31,32).

It is shown that, despite the activation of early response genes after subdiaphragmatic vagotomy, hindering of the multiplication of liver parenchymal cells still occurs. This indicates that only delay of the emergence of mitosis in vagotomized animals on later periods (4 days) of the subdiaphragmatic vagotomy might be determined by the activation of the alternative signal path (33).

From the above, it follows that study of the liver regeneration interconnected cascade signals, mediated cytokines, growth factors and protein kinases, is very important (1,2) In particular, it is established that signal, which reached the cell by means of various factors, causes a wide range of responses (proliferation, differentiation, apoptosis, etc.) with cascade activation of intracellular signalling pathways of protein kinases (with mitogen-activated protein kinases - MAPK). Despite the numerous

studies, the following questions still remain unanswered:

1. Which signal path determines polyploidization of cells for example?
2. Is this signal path independent or is it activating another process (eg. proliferation, apoptosis)?
3. Does the only one signal cascade provide manifold increase of the genome or is there any reserve mechanisms?
4. Is/are the signal path/s of physiological and pathological polyploidization different and etc.

Acknowledgement

This work was supported by Shota Rustaveli National Science Foundation (SRNSF) [DP2016_22, New Interfaculty Interdisciplinary Structured PhD Programme "Translational Biomedicine" (Direction – "Hepatology")].

References

1. Fausto N, Campbell JS, Riehle KJ. Liver regeneration. Hepatology. 2006 Feb;43(S1):S45-53.
2. Michalopoulos GK. Liver regeneration. Journal of cellular physiology. 2007 Nov 1;213(2):286-300.
3. Bivalkevich N. Karaman U. Mechanisms of Rats Liver Regeneration During Alimentary Dyslipidemic Health. Medical ecology. The science. 2009 e4-5 (pp38-40) ; (Russia)
4. Wang MJ, Chen F, Lau JT, Hu YP. Hepatocyte polyploidization and its association with pathophysiological processes. Cell death & disease. 2017 May;8(5):e2805.
5. Bakuradze E The characteristics of the liver regeneration in conditions of cholestasis. The thesis for gaining degree of candidate of biological sciences. 2006; (Georgia)
6. Minamishima YA, Nakayama K, Nakayama KI. Recovery of liver mass without proliferation of hepatocytes after partial hepatectomy in Skp2-deficient mice. Cancer Research. 2002 Feb 15;62(4):995-9
7. Losick VP. Wound-induced polyploidy is required for tissue repair. Advances in wound care. 2016 Jun 1;5(6):271-8.
8. Ramsey J, Schemske DW. Pathways, mechanisms, and rates of polyploid formation in flowering plants. Annual review of ecology and systematics. 1998 Nov;29(1):467-501.
9. Otto SP. The evolutionary consequences of polyploidy. Cell. 2007 Nov 2;131 (3):452-62.
10. Anatskaya OV, Vinogradov AE, Kudryavtsev BN. Hepatocyte polyploidy and metabolism/life-history traits: hypotheses testing. Journal of theoretical biology. 1994 May 21;168(2):191-9.
11. Geschwind II, Alfert M, Schooley C. The effects of thyroxin and growth hormone on liver polyploidy. The Biological Bulletin. 1960 Feb;118(1):66-9.
12. Nadal C, Zajdela F. Polyploïdie somatique dans le foie de rat: I. Le rôle des cellules binucléées dans la genèse des cellules polyploïdes. Experimental Cell Research. 1966 Apr 1;42(1):99-116.
13. Brodsky V, Uryvaeva I.V. Cell polyploidy. Proliferation and differentiation. Nauca. Moscow.1981. p259.(Russia)
14. Saeter G, Schwarze PE, Nesland JM, Juul N, Pettersen EO, Seglen PO. The polyploidizing growth pattern of normal rat liver is replaced by divisional, diploid growth in hepatocellular nodules and carcinomas. Carcinogenesis. 1988 Jun 1;9(6):939-45.
15. Gerlyng P, Åbyholm A, Grotmol T, Erikstein B, Huitfeldt HS, Stokke T, Seglen PO. Binucleation and polyploidization patterns in developmental and regenerative rat liver growth. Cell proliferation. 1993 Nov;26(6):557-65.
16. Gentric G, Desdouets C. Polyploidization in liver tissue. The American journal of pathology. 2014 Feb 1;184(2):322-31.
17. Lejava T. Human Genetics. General parts of Edition of TSU 1989. pp 153-155 (Georgia)
18. Li F, Wang X, Capasso JM, Gerdes AM. Rapid transition of cardiac myocytes from hyperplasia to hypertrophy during postnatal development. Journal of molecular and cellular cardiology. 1996 Aug 1;28(8):1737-46.
19. Ulumbekov E. Histology. Pathology processes. 1998. pp393-400 (Russia)
20. Shatirishvili A. Tsagareli S. Tsartsidze M. General Biology. Tbilisi 1999. pp 305-306 (Georgia)
21. Krstic RV. Illustrated encyclopedia of human histology. Springer Science & Business Media; 2012 Dec 6.
22. Duelli D, Lazebnik Y. Cell-to-cell fusion as a link between viruses and cancer. Nature Reviews Cancer. 2007 Dec;7(12):968.
23. Gupta S. Hepatic polyploidy and liver growth control. InSeminars in cancer biology 2000 Jun 1 (Vol. 10, No. 3, pp. 161-171). Academic Press.
24. Kudryavtsev BN, Kudryavtseva MV, Sakuta GA, Stein GI. Human hepatocyte polyploidization kinetics in the course of life cycle. Virchows Archiv B. 1993 Dec 1;64(1):387.
25. Guidotti JE, Brégerie O, Robert A, Debey P, Brechot C, Desdouets C. Liver cell polyploidization: a pivotal role for binuclear hepatocytes. Journal of Biological Chemistry. 2003 May 23;278(21):19095-101.
26. Celton-Morizur S, Merlen G, Couton D, Margall-Ducos G, Desdouets C. The insulin/Akt pathway controls a specific cell division program that leads to generation of binucleated tetraploid liver cells in rodents. The Journal of clinical investigation. 2009 Jul 1;119(7):1880-7.
27. Leffert HL, Koch KS, Moran T, Rubalcava B. Hormonal control of rat liver regeneration. Gastroenterology. 1979 Jun 1;76(6):1470-82.
28. Kelley-Loughnane N, Sabla GE, Ley-Ebert C, Aronow BJ, Bezerra JA. Independent and overlapping transcriptional activation during liver development and regeneration in mice. Hepatology. 2002 Mar 1;35(3):525-34.
29. Gentric G, Celton-Morizur S, Desdouets C. Polyploidy and liver proliferation. Clinics and research in hepatology and gastroenterology. 2012 Feb 1;36 (1):29-34.
30. Giridhar R. Gorla,Harmeet Malhi,Sanjeev Gupta Polyploidy associated with oxidative injury attenuates proliferative potential of cells. J Cell Sci 2001 Aug;114(Pt 16):2943-51;
31. Ohtake M, Sakaguchi T, Yoshida K, Muto T. Hepatic branch vagotomy can suppress liver regeneration in partially hepatectomized rats. HPB Surgery. 1993;6(4):277-86.
32. Linard C, Marquette C, Clarençon D, Galonnier M, Mathieu J, Pennequin A, Benderitter M, Gourmelon P. Acute ileal inflammatory cytokine response induced by irradiation is modulated by subdiaphragmatic vagotomy. Journal of neuroimmunology. 2005 Nov 1;168(1-2):83-95.
33. Qemoklidze S. Bakuradze E, Modebadze I, Dekanoidze D, Ninua L, Dzidziguri D, Influence of the Truncal Vagotomy on the liver Regeneration. Abstracts of the scientific board of 13th ESS Meeting. 2009. Octomber 4th Tbilisi, (Georgia)

Management of Infertility in Women with Ovarian Endometrioma

Grigalashvili N.

Abstract

Introduction: In the current article the attempt is made to summarize the evidence on the benefits of laparoscopic cystectomy in the treatment of women infertility.
Method: The data concerning the issue was collected from the Google, NCBI and PubMed database by the use of keywords, such as: ovarian endometrioma, infertility, diagnosis, treatment . The years for search were 1990-2018.
Conclusion: The positive aspects of laparoscopic removal of endometrial cyst are such as the high rate of spontaneous pregnancy as well as successful in vitro fertilization and birth giving after laparoscopy. At the same time, we stress the importance of the rising awareness of endometriosis in wider community to encourage women with endometriosis symptoms , especially those with unusual symptomatology, to seek for medical aid timely. **(TCM-GMJ March 2019; 4 (1):P11-P14)**

Keywords: Ovarian endometrioma; Diagnosis; Laparoscopy; Fertility.

Following article is aimed at discussing the problems of the treatment of ovarian endometrioma (OMA), with respect to the management of infertility in OMA sufferers. The data was collected from the Google, NCBI and PubMed database by the use of keywords, such as: ovarian endometrioma, infertility, diagnosis, treatment . The years for search were 1990-2018.

Endometriosis is defined as an inflammatory disease, characterized by the development of endometrial tissue out of the uterus (1). Three principal issues need to be considered in the clinical treatment of endometriosis: pain, recurrence, and infertility. As a common chronic disease, endometriosis with its pathological symptomatology affects quality of life of the patients. Women with endometriosis are impaired physically and socially. At the same time, infertility is the leading cause of psychological problems in endometriosis sufferers (2,3).

50% of the women, addressing physicians because of infertility in the USA and Europe,are diagnosed with endometriosis (4). About 35000 women are infertile in Georgia (5).

Among clinically distinct forms of endometrial growths, such as peritoneal endometriosis, deeply infiltrating endometriosis and cystic OMA (Figure 1), the latter affects 17-44% of women, diagnosed with endometriosis in reproductive age (6-8). OMA affects normal ovarian function as long as it contains mediating enzymes, causing cellular damage, as well as inflammatory substances, reactive oxygen and iron. In contrast to other benign cysts, OMA causes serious oxidative stress in the healthy ovarian cortex and inhibits the angiogenesis in the ovary. As a result, oogenesis is deeply affected and women with OMA suffer from infertility. OMA has a negative influence on the development of oocytes and fertilization as well as on the outcome of pregnancy, mainly due to the implantation problems (9).

Infertility is considered as one of the leading symptoms of the OMA, affecting about 35-50% of women with endometriosis (10). The rate of spontaneous fertilization in the OMA sufferers varies between 31% (11) and 43% (12) and monthly rate of pregnancy makes one third of the pregnancy rate from 2% to 10% in healthy women (13,14). According to the retrospective analysis, the rate of endometriosis in infertile women reaches 46.05% in Georgia (15).

The problem, we would like to note here, is related to the delay in diagnosis of endometriosis. The onset of the disease is characterized by pain in the pelvic, dysmenorrhea, bleeding and pain during sexual intercourse. After the onset of the pain, teenagers refer to clinic after 2 years on average, women aged 20-29 - in 6 months and those aged 30 and more – in 2 months. However, in some particular cases this period may be prolonged to 3-13 years (16,17). Due attention should be paid to the reasons behind the delayed visit to the clinic. On the one hand, women prefer to hide the problem related to the reproductive system and do not want to discuss it even with a physician (18). In our opinion, raising endometriosis awareness campaign in mass-media as well as discussion of the problem with teenagers in schools, with participa-

From the [1]Amtel Hospital, Tsinandali st. 9, 0144, Tbilisi, Georgia
[2]New Hospitals, Krtsanisi st. 12, 0144, Tbilisi, Georgia
Received August 8, 2018; accepted December 10 , 2018.
Address requests to: Nugesha Grigalashvili
E-mail: nugeshagrigalashvili@gmail.com
Copyright © 2019 Translational and Clinical Medicine-Georgian Medical Journal. Published online www.tcm.tsu.ge

tion of the specialists in the field, will help to deal with these problems. On the other hand, some physical characteristics of endometriosis in the young age are responsible for the delayed diagnosis. Endometriosis in girls may develop before the beginning of the menstrual cycle, the symptoms of the disease in teenagers does not have classical character as compared to endometriosis in adults and in some clinical cases, normal menstrual cycle may develop in the presence of endometriosis (18, 19). Physicians should be more attentive to such clinical cases and convince patient to undergo laparoscopic diagnostics of endometriosis.

Another problem of the treatment of endometriosis is a controversy with respect to which approach to the treatment should be used. Generally, laparoscopy is considered as a Gold Standard for the treatment of endometriosis and OMA in particular. While surgical treatment may improve spontaneous pregnancy rates by restoring the pelvic anatomy, it remains unclear as to whether surgical intervention on the ovary itself is beneficial as it may not reverse the inflammatory and bio molecular changes, shown to influence fertilization and implantation. Furthermore, there are concerns regarding the safety of surgical treatments, laparotomy in particular, with a reported reduction in the ovarian reserve, damage of adjacent tissues and the risk of requiring an oophorectomy (20-22). This conflict suggests that management should be individualized and based upon clinical factors, including pain symptoms and the size of the cysts as well as concerns over potential malignancy. Although the rate of the transformation of the benign endometrial cyst into the malignant is only 0.7-1% (0.7-1% (7), women with the risk of cancer should consult to radiologist prior to undergoing the surgical intervention for treating infertility.

In our opinion, the decision about surgical intervention should be based on clear understanding of the benefits of surgical treatment per se and in comparison to other interventions. We provide the summary of the findings, which point to the positive effect of laparoscopic cystectomy in the treatment of infertility in women with OMA.

The study findings argue for the better outcome of the laparoscopic ovarian cystectomy as compared to the drainage and coagulation. Authors (23) reported on 16.2% of pregnancy in 21 months of postoperative observation. According to recent studies the rate of pregnancy during the 12 months of postoperative observation was 60% (24), 30-67% after the 1 year of cystectomy (13) and 54% in much long-lasting postoperative observation of OMA patients (25). At the same time, the positive effect of laparoscopic removal of the endometriotic cyst was the same in patients with different stages of the disease (24). Although the percentage of patients with the 4-th stage was lower as compared to others, the difference was not statistically reliable. As compared to the 30% rate of pregnancy after coagulation of endometriotic cyst (26,27), the pregnancy parameters after laparoscopy are really promising. According to Georgian researchers (15), pregnancy rate in infertile patients with minimal or mild endometriosis after laparoscopic coagulation of endometrial lesions during 9-12month follow-up was 34.2 % (69 pregnancies from 202 women), while in laparoscopic excision group pregnancy rates were significantly higher – 49.3% (37 pregnancies from 75 women).

Usually, the size of OMA varies from the microscopic to 4 cm. However, larger cysts are observed in some clinical cases as well (28). Laparoscopic removal of endometrial cyst is strongly recommended when the size of the cyst exceeds the 3 cm. Surgical laparoscopic intervention in such case minimizes the pain, postpones the recurrence (29,30). Postoperative hormonal treatment helps in prevention of the recurrence for longer time (31). However, hormonal treatment does not improve spontaneous pregnancy rates and therefore, it is not desirable in patients, who try to conceive (13). At the same time, the decision to proceed with surgery should be considered carefully if patients have had previous ovarian surgery. In clinical cases with endometrioma larger than 3 cm, cystectomy is indicated prior to Assisted reproductive technology when it is associated with pain or inaccessibility of follicles (32).

Laparoscopic treatment of endometrioma is widely practiced before in vitro fertilization. According to authors (33), after surgical intervention, the rate of successful delivery, spontaneous pregnancy after first birth giving and miscarriage was the same as in the control group. However, the patients were treated with high doses of gonadotropins.

Contemporary studies of pharmacotherapy are promising with respect to solving the problem of the reduction of ovarian reserve after laparoscopy. The agents of the first line are such as non-steroid analgesics, hormonal contraceptives and progesterone (34,35).

There are alternatives to laparoscopy as well. Transvaginal aspiration of endometrioma with ultrasound control has been practiced since the end of the 20-th century (36). The limitation of this method is that it can not be used in women, especially teenagers, who are still not sexually active. Sclerotherapy is one more alternative to laparoscopy, which is recognized as a non-surgical technics, preserving ovarian reserve (37,38). Sclerotherapy agents infused into the cystic cavity are washed out from the cyst or remain in-situ. In both cases the agents disrupt the epithelial underlining of the cystic cavity, leading to the inflammation, fibrosis and finally, to the cyst obliteration (39). However, the benefit of the sclerotherapy with respect to the management of the fertility of women with OMA is still not clear (6).

In conclusion: There are many pros and cons with respect to the surgical laparoscopic approach of the treatment of OMA. We made an attempt to collect the evidence on the benefits of laparoscopic cystectomy in the treatment of women with infertility. The positive aspects of laparoscopic removal of endometrial cyst are such as: high rate of spontaneous pregnancy, as well as successful in vitro fertilization and life birth after laparoscopy. At the same time, we emphasize the importance of raising awareness about endometriosis in wider community to encourage women with endometriosis symptoms to seek for medical aid timely. At the same time, in our opinion,

symptoms of endometriosis among adolescents, unusual for classical endometriosis symptomatology,observed in the adults, deserve due attention for timely diagnostics of endometriosis.

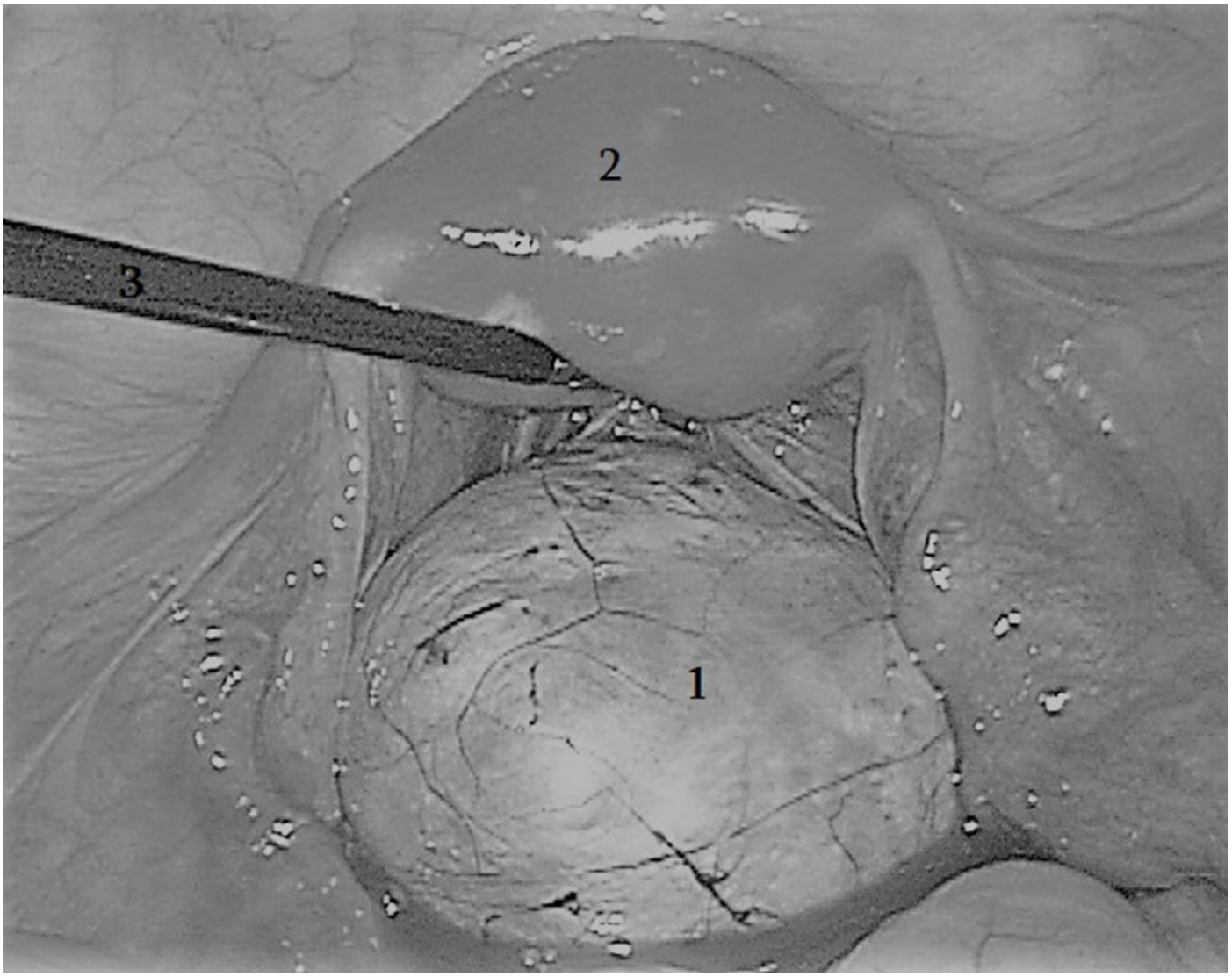

Figure 1: Ovarian endometrioma
1-endometroid cyst, 2- adjacent ovarian tissue, retracted by the surgical instrument (3).

References

1. Johnson NP, Hummelshoj L, Adamson GD, Keckstein J, Taylor HS, Abrao MS, Bush D, Kiesel L, Tamimi R, Sharpe-Timms KL, Rombauts L. World Endometriosis Society consensus on the classification of endometriosis. Human Reproduction. 2017 Jan 23;32(2):315-24.
2. De Abreu LG, De Carvalho BR, Barcelos ID, de Sá Rosa e Silva AC, Ferriani RA, Rosa e Silva JC. Laparoscopic treatment of endometriosis focusing on fertility outcomes. Expert Review of Obstetrics & Gynecology. 2008 Mar 1;3(2):203-9.
3. AlKudmani B, Gat I, Buell D, Salman J, Zohni K, Librach C, Sharma P. In vitro fertilization success rates after surgically treated endometriosis and effect of time interval between surgery and in vitro fertilization. Journal of minimally invasive gynecology. 2018 Jan 1;25(1):99-104.
4. Schuster M, Mackeen DA. Fetal endometriosis: a case report. Fertility and Sterility. 2015;(103):160–2.
5. Verulava T, Khabeishvili M. The treatment of infertility in georgia. Health Policy and Insurance. 2018; July, http://hepoins.com/index.php/component/k2/item/60-invitro
6. Cohen A, Almog B, Tulandi T. Sclerotherapy of ovarian endometrioma. Fertility and Sterility. 2017; (108):117–24
7. Kaponis A, Taniguchi F, Azuma Y, et al. Current Treatment of Endometrioma. Obstetrical and Gyneclogical Survay. 2015; 70 (3): 183-5
8. Sanchez AM, Vigano P, Somigliana E, Panina-Bordignon P, Vercellini P, Candiani M. The distinguishing cellular and molecular features of the endometriotic ovarian cyst: from pathophysiology to the potential endometrioma -mediated damage to the ovary. Human Reproduction Update. 2014; (20):217–30.
9. Pahlajani G, Falcone T. Laparoscopic surgery for endometriosis- associated infertility: a patopsychologic approach. Gynecological Surgery. 2010; (7):319 –28
10. Giudice LC, Kao LC. Endometriosis. Lancet. 2004;364:1789–99
11. Benaglia L, Somigliana E, Vercellini P, Abbiati A, Ragni G, Fedele L. Endometriotic ovarian cysts negatively affect the rate of spontaneous ovulation. Human Reproduction. 2009; (24):2183–6.
12. Somigliana E, Benaglia L, Paffoni A, Busnelli A, Vigano P, Vercellini P. Risks of conservative management in women with ovarian endometriomas undergoing IVF. Human Reproduction Update. 2015; (21):486–99.
13. Mavrelos D, Saridogan E. Treatment of Endometriosis in Women Desiring Fertility. The Journal of Obstetrics and Gynecology of India. 2015 January–February 65(1):11–6.
14. Gupta S, Goldberg JM, Aziz N, et al. Pathogenic mechanisms in endometri-

osis-associated infertility. Fertility and Sterility. 2008; (90):247–57.
15. Gvenetadze A, Iremadze L, Dzotsenidze T, Sichinava L, Tandashvili L. Pregnancy rates after laparoscopic treatment of minimal or mild endometriosis - 4,5 years of experience.in: Abstracts of the 26th Annual Congress of the European Society for Gynaecological Endoscopy (ESGE) 18th – 21st October, Sueno Belek – Antalya – Turkey. 2017:221
16. Arruda MS, Petta CA, Abrao MS. Time elapsed from onset of symptoms of endometriosis in a cohort study of Brazilian women. Human Reprodyction. 2003;(18):756-9
17. Hudelist G, Fritzer N, Thomas A, et al. Diagnostic delay for endometriosis in Austria and Germany: causes and possible consequences. Human Reproduction. 2012; 27(12):3412-6
18. Brosens I, Gordts S, Benagiano G. Endometriosis in adolescents is a hidden, progressive and severe disease that deserves attention, not just compassion. Human Reproduction. 2013; (28):2026–31.
19. Laufer MR, Goitein L, Bush M, et al. Prevalence of endometriosis in adolescent girls with chronic pelvic pain not responding to conventional therapy. Journal of Pediatric and Adolescent Gynecology. 1997;(10):199-202
20. Jayaprakasan K, Becker C, Mittal M. On behalf of the Royal College of Obstetricians andGynaecologists. The Effect of Surgery for Endometriomas on Fertility. Scientific Impact Paper No. 55. International Journal of Obstetrics and Gynecology. 2017;(125):19–28
21. Hirokawa W, Iwase A, Goto M, et al. The post-operative decline in serum anti-Mullerian hormone correlates with the bilaterality and severity of endometriosis. Human Reproduction. 2011; (26):904–10.
22. Raffi F, Metwally M, Amer S. The impact of excision of ovarian endometrioma on ovarian reserve: a systematic review and metaanalysis. J Clinical Endocrinology and Metabolism. 2012; (97): 3146–54.
23. Kikuchi I, Takeuchi H, Kitade M, Shimanuki H, Kumakiri J, Kinoshita K. Recurrence rate of endometriomas following a laparoscopic cystectomy. Acta Obstetrics and Gynecology Scandinavia. 2006; 85(9):1120-24.
24. Lee H, Lee J., Ku SY, et al. Natural conception rate following laparoscopic surgery in infertile women with endometriosis. Clin Exp Reprod Med. 2013;40(1):29-32
25. Maul LV., Morrision JE, Schollmeyer Th., Alkatout I.,Mettler L. Surgical Therapy of Ovarian Endometrioma:Recurrence and Pregnancy Rates. Journal of the society of laparoscopic surgeons, 2014; 18 (3): 1-6
26. Marcoux S, Maheux R, Berube S. Laparoscopic surgery in infertile women with minimal or mild endometriosis. New England Journal of Medicine. 1997; (337):217–22
27. Vercellini P, Fedele L, Aimi G, Pietropaolo G, Consonni D, Crosignani PG. Association between endometriosis stage, lesion type, patient characteristics and severity of pelvic pain symptoms: a multivariate analysis of over 1000 patients. Human Reproduction. 2007; (22):266–71.
28. Şimşek M, Kuloğlu T, Pala, Boztosun A, Can B, Atilgan R. The effect of ethanol sclerotherapy of 5 minutes duration on cyst diameter and rat ovarian tissue in simple ovarian cysts. Dove Medical Press, 2015; (9):1341-7.
29. Guo SW. Recurrence of endometriosis and its control. Human Reproduction Update. 2009;15:441–461.
30. Hart RJ, Hickey M, Maouris P, Buckett W, et al. Excision surgery versus ablative surgery for ovarian endometriomata. Cochrane Library. 2008; (4):1–25
31. Yang YP, Wang Y, Jie Yang JY, et al. Adolescent Endometriosis in China: A Retrospective Analysis of 63 Cases. J Pediatrica and Adolescent Gynecology. 2012;(25):295-9.
32. GPP ESHRE Guideline. Hum Reprod 2014; 29 (3):400-12.
33. Hamdan M, Dunselman G, Li TC, Cheong Y. The impact of endometrioma on IVF/ICSI outcomes: a systematic review and meta-analysis. Human Reproduction Update 2015; (21):809–25.
34. Owczarek D, Malinowski A, Wilczyński M. Ovarian reserve evaluation after laparoscopic cyst enucleation, depending on applied haemostasis technique and with particular consideration of endometrial cysts. Menopause Review. 2018; 17(1): 22-7.
35. Lagana AS, Vitale SG, Granese R. Clinical dynamics of Dienogest for the treatment of endometriosis: from bench to bedside. Expert Opinion in Drug Metabolism Toxicology 2017; 13: 593-596.
36. Aboulghar MA, Mansour RT, Serour GI, Rizk B. Ultrasonic transvaginal aspiration of endometriotic cysts: an optional line of treatment in selected cases of endometriosis. Human Reproduction. 1991;6(10):1408-10.
37. Dunselman, N. Vermeulen, C. Becker, et al. ESHRE guideline: management of women with endometriosis. Human Reproduction, 2014; 29 (3):400–12.
38. Castellarnau VM, Ponce SJ, Carreras CR, Cayuela FE, Garcia TA. Preliminary results: ethanol sclerotherapy after ultrasoundguided fine needle aspiration without anesthesia in the management of simple ovarian cysts. J Minimal Invasive Gynecology. 2015; (22):475–82.
39. Albanese G, Kondo KL. Pharmacology of sclerotherapy. Seminars in Interventional Radiology. 2010;(27):391–9.

TRANSLATIONAL AND CLINICAL MEDICINE - Georgian Medical Journal

tcm.tsu.ge/index.php/TCM-GMJ/article/view/135

Minimal fresh gas flow anesthesia

Ioseb Begashvili

Abstract

Background: Reducing the fresh gas flow ≤ 0.5 L/min during maintenance of anesthesia is associated with several benefits. Enhanced preservation of temperature and humidity, cost savings through more efficient utilization of inhaled anesthetics, and environmental considerations are three key reasons to implement minimal-flow and closed-circuit anesthesia, although potential risks are hypoxic gas mixtures and inadequate depth of anesthesia. The third-generation inhaled anesthetics have low blood and low tissue solubility, which facilitates rapid equilibration between the alveolar and effect site (brain) concentrations and makes them ideally suited for low-flow techniques. The use of modern anesthesia machines designed for minimal-flow techniques, leak-free circle systems, highly efficient CO_2 absorbers, and the common practice of utilizing real time multi gas monitor, including essential alarm systems, allow for safe and cost effective minimal flow techniques during maintenance of anesthesia.

Aim: The aim of this brief review is to provide an update on the theory regarding minimal fresh gas flow techniques for inhaled general anesthesia. The article also includes an update and discussion of the practical aspects associated with minimal flow anesthesia, including the advantages, potential limitations, and safety considerations of this important anesthesia technique.

Materials and Methods: We reviewed most of the existing literature in this field. We summarized all of them to approve safety and advantage of this type of anesthesia technique.

Conclusion: Literature review proves that with our modern anesthesia machines, reducing the fresh gas flow of oxygen to 0.3-0.5 L/min and using third generation inhaled anesthetics provide a reassuringly safe anesthesia technique. This environmentally friendly practice can easily be implemented for elective anesthesia. Furthermore it will facilitate cost savings and improve temperature homeostasis.

Keywords: minimal low flow anesthesia rebreathing systems

Keywords

Keywords

minimal low flow anesthesia rebreathing systems

References

FOLDES FF, CERAVOLO AJ, CARPENTER SL. The administration of nitrous-oxygen anesthesia in closed systems. Annals of Surgery. 1952; 136(6):978–981.

Virtue RW. Minimal-flow Nitrous Oxide Anesthesia. Anesthes. 1974 Feb 1; 40(2):196–8.

Baxter AD. Low and minimal flow inhalational anesthesia. Canadian Journal of Anaesthesia. 1997; 44(6):643–53.

Kleemann PP. The climatisation of anesthetic gases under conditions of high flow to low flow. Acta Anaesthesiologica Belgica. 1990;41(3):189–200.

Branson RD, Campbell RS, Davis K, Porembka DT. Anaesthesia circuits, humidity output, and mucociliary structure and function. Anaesthesia and Intensive Care. 1998;26(2):178–183.

Baum J, Züchner K, Hölscher U, Sievert B, Stanke HG, Gruchmann T, et al. Klimatisierung von narkosegasen bei einsatz unterschiedlicher patientenschlauchsysteme. Anaesthesist. 2000;49(5):402–411.

Bengtson JP, Bengtson A, Stenqvist O. The circle system as a humidifier. British Journal of Anaesthesia. 1989;63(4):453–457.

Kleemann PP. Humidity of anesthetic gases with respect to low flow anesthesia. Anaesthesia and Intensive Care. 1994;22(4):396–408.

Bilgi M, Goksu S, Mizrak A, Cevik C, Gul R, Koruk S, et al. Comparison of the effects of low-flow and high-flow inhalational anesthesia with nitrous oxide and desflurane on mucociliary activity and pulmonary function tests. European Journal of Anaesthesiology. 2011;28(4):279–283.

Langbein T, Sonntag H, Trapp D, Hoffmann A, Malms W, Roth EP, et al. Volatile anesthetics and the atmosphere: atmospheric lifetimes and atmospheric effects of halothane, enflurane, isoflurane, desflurane and sevoflurane. British Journal of Anaesthesia. 1999;82(1):66–73.

Parker NW, Behringer EC. Nitrous oxide: A global toxicological effect to consider. Vol. 110. 2009. 1195 p.

Ishizawa Y. Special article: general anesthetic gases and the global environment. Anesthesia and analgesia. 2011;112(1):213–7.

Ryan SM, Nielsen CJ. Global warming potential of inhaled anesthetics: Application to clinical use. Anesthesia and Analgesia. 2010;111(1):92–98.

Ekbom K, Assareh H, Anderson RE, Jakobsson JG. The effects of fresh gas flow on the amount of sevoflurane vaporized during 1 minimum alveolar concentration anesthesia for day surgery: A clinical study. Acta Anaesthesiologica Scandinavica. 2007;51(3):290–3.

Eger EI, White PF, Bogetz MS. Clinical and economic factors important to anesthetic choice for day- case surgery. PharmacoEconomics. 2000;17(3):245–62.

Weiskopf RB, Eger EI. Comparing the costs of inhaled anesthetics. Anesthesiology. 1993;79(6):1413–8.

Ekbom K, Assareh H, Anderson RE, Jakobsson JG. The effects of fresh gas flow on the amount of sevoflurane vaporized during 1 minimum alveolar concentration anesthesia for day surgery: A clinical study. Acta Anaesthesiologica Scandinavica. 2007;51(3):290–3.

Lindqvist M, Jakobsson J. Minimal flow anesthesia for short elective day case surgery; high vaporiser settings are needed but still cost-effective. Ambulatory Surgery. 2011;17(2):27–9.

Doolke A, Cannerfelt R, Anderson R, Jakobsson J. The effects of lowering fresh gas flow during sevoflurane anesthesia: A clinical study in patients having elective knee arthroscopy. Ambulatory Surgery. 2001;9(2):95–8.

Christian Hönemann, Bert Mierke. Low-flow, minimal-flow and metabolic-flow anesthesia Clinical techniques for use with rebreathing systems. Drägerwerk AG & Co. KGaA; 2015.

Barton F, Nunn JF. TOTALLY CLOSED CIRCUIT NITROUS OXIDEOXYGEN ANAESTHESIA. British Journal of Anaesthesia. 1975;47(3):350–7.

Bengtson JP, Sonander H, Stenqvist O. Gaseous homeostasis during low-flow anesthesia. Acta Anaesthesiologica Scandinavica. 1988;32(7):516–21.

Morita S, Latta W, Hambro K, Snider MT. Accumulation of methane, acetone, and nitrogen in the inspired gas during closed-circuit anesthesia. Anesthesia and analgesia. 1985;64(3):343–7.

Versichelen L, Rolly G, Vermeulen H. Accumulation of foreign gases during closed-system anesthesia. British Journal of Anaesthesia. 1996;76(5):668–72.

Ziemann-Gimmel P, Schwartz DE. Increased carboxyhemoglobin in a patient with a large retroperitoneal hematoma. Anesthesia and Analgesia. 2004;99(6):1800–2.

Mazze RI. Composition of CO(2) absorbents. Anesth Analg [Internet]. 2001 [cited 2018 Feb 17];92(5).

Struys MMRF, Bouche MPLA, Rolly G, Vandevivere YDI, Dyzers D, Goeteyn W, et al. Production of compound A and carbon monoxide in circle systems: An in vitro comparison of two carbon dioxide absorbents. Anaesthesia. 2004;59(6):584–9.

Higuchi H, Adachi Y, Arimura S, Kanno M, Satoh T. The carbon dioxide absorption capacity of Amsorb® is half that of soda lime. Anesthesia and Analgesia. 2001;93(1):221–5.

Kharasch ED, Powers KM, Artru AA. Comparison of amsorb®, sodalime, and baralyme® degradation of volatile anesthetics and formation of carbon monoxide and compound A in swine in vivo. Anesthesiology. 2002;96(1):173–82.

Eriksson, Stellan, and Sixten Bredbacka, '[Better Gas Anesthesia Technique Better for Environment, Economics and Patients. Systematic Improvement Work Gave Results].', Lakartidningen, 108, 1190–92

Avidan MS, Jacobsohn E, Glick D, Burnside BA, Zhang L, Villafranca A, et al. Prevention of Intraoperative Awareness in a High-Risk Surgical Population. New England Journal of Medicine. 2011;365(7):591–600.

Baum JA. The carrier gas in anesthesia: Nitrous oxide/oxygen, medical air/oxygen and pure oxygen. Current Opinion in Anaesthesiology. 2004;17(6):513–6.

Refbacks

There are currently no refbacks.

Become a REVIEWER

ISSN: 2346-8491 (online)